

Immunization with neuronal nicotinic acetylcholine receptor induces neurological autoimmune disease

Vanda A. Lennon, ... , Joseph H. Szurszewski, Steven Vernino

J Clin Invest. 2003;111(6):907-913. <https://doi.org/10.1172/JCI17429>.

Article Autoimmunity

Neuronal nicotinic AChRs (nAChRs) are implicated in the pathogenesis of diverse neurological disorders and in the regulation of small-cell lung carcinoma growth. Twelve subunits have been identified in vertebrates, and mutations of one are recognized in a rare form of human epilepsy. Mice with genetically manipulated neuronal nAChR subunits exhibit behavioral or autonomic phenotypes. Here, we report the first model of an acquired neuronal nAChR disorder and evidence for its pertinence to paraneoplastic neurological autoimmunity. Rabbits immunized once with recombinant $\alpha 3$ subunit (residues 1–205) develop profound gastrointestinal hypomotility, dilated pupils with impaired light response, and grossly distended bladders. As in patients with idiopathic and paraneoplastic autoimmune autonomic neuropathy, the severity parallels serum levels of ganglionic nAChR autoantibody. Failure of neurotransmission through abdominal sympathetic ganglia, with retention of neuronal viability, confirms that the disorder is a postsynaptic channelopathy. In addition, we found ganglionic nAChR protein in small-cell carcinoma lines, identifying this cancer as a potential initiator of ganglionic nAChR autoimmunity. The data support our hypothesis that immune responses driven by distinct neuronal nAChR subtypes expressed in small-cell carcinomas account for several lung cancer–related paraneoplastic disorders affecting cholinergic systems, including autoimmune autonomic neuropathy, seizures, dementia, and movement disorders.

Find the latest version:

<https://jci.me/17429/pdf>



Immunization with neuronal nicotinic acetylcholine receptor induces neurological autoimmune disease

See the related Commentary beginning on page 797.

Vanda A. Lennon,^{1,2,3} Leonid G. Ermilov,⁴ Joseph H. Szurszewski,⁴ and Steven Vernino²

¹Department of Immunology,

²Department of Neurology,

³Department of Laboratory Medicine and Pathology, and

⁴Department of Physiology, Mayo Graduate and Medical Schools and Mayo Clinic, Rochester, Minnesota, USA

Neuronal nicotinic AChRs (nAChRs) are implicated in the pathogenesis of diverse neurological disorders and in the regulation of small-cell lung carcinoma growth. Twelve subunits have been identified in vertebrates, and mutations of one are recognized in a rare form of human epilepsy. Mice with genetically manipulated neuronal nAChR subunits exhibit behavioral or autonomic phenotypes. Here, we report the first model of an acquired neuronal nAChR disorder and evidence for its pertinence to paraneoplastic neurological autoimmunity. Rabbits immunized once with recombinant $\alpha 3$ subunit (residues 1–205) develop profound gastrointestinal hypomotility, dilated pupils with impaired light response, and grossly distended bladders. As in patients with idiopathic and paraneoplastic autoimmune autonomic neuropathy, the severity parallels serum levels of ganglionic nAChR autoantibody. Failure of neurotransmission through abdominal sympathetic ganglia, with retention of neuronal viability, confirms that the disorder is a postsynaptic channelopathy. In addition, we found ganglionic nAChR protein in small-cell carcinoma lines, identifying this cancer as a potential initiator of ganglionic nAChR autoimmunity. The data support our hypothesis that immune responses driven by distinct neuronal nAChR subtypes expressed in small-cell carcinomas account for several lung cancer-related paraneoplastic disorders affecting cholinergic systems, including autoimmune autonomic neuropathy, seizures, dementia, and movement disorders.

J. Clin. Invest. 111:907–913 (2003). doi:10.1172/JCI200317429.

Introduction

Autoimmunity is commonly invoked as a basis for neurological diseases, both paraneoplastic (1) and idiopathic (2, 3), but proof of autoimmune pathogenesis is lacking in most instances, and few valid animal models exist. The paradigm of neurological autoimmunity is myasthenia gravis (MG). Immunization with muscle-type nicotinic AChR (nAChR) protein readily induces experimental autoimmune MG (EAMG) in rabbits and rodents (4, 5), and muscle nAChR-specific antibodies are the proven cause of impaired neuromuscular transmission (6). Neuronal nAChRs are implicated in numerous disease states, including dementia, epilepsy, Parkinson's disease, dysautonomia, and schizophrenia (7, 8). Twelve vertebrate neuronal nAChR subunits have been discovered to date (9), and mice created with

mutations of nAChR genes exhibit behavioral and autonomic phenotypes. Mutations of the $\alpha 4$ subunit have been found in a rare, dominantly inherited form of epilepsy (7, 8). Despite these advances, no neurological impairment has yet been described in animals immunized with a neuronal nAChR.

We recently defined a population of patients with autoimmune autonomic neuropathy (AAN, also known as subacute pandysautonomia) through detection of serum autoantibodies that bind to neuronal nAChRs of autonomic ganglion-type (10). Like MG, AAN sometimes occurs in a paraneoplastic context. It is associated most frequently with thymoma or small-cell lung carcinoma (SCLC). AAN presents as a subacute, monophasic, and life-threatening illness with slow and incomplete recovery. Patients experience parasympathetic and sympathetic autonomic failure, with prominent gastrointestinal dysfunction.

The ganglionic nAChRs that mediate fast neurotransmission at synapses in the mammalian sympathetic and parasympathetic nervous system are pentameric ligand-gated cation channels containing two $\alpha 3$ subunits. These subunits contribute to binding sites for acetylcholine and the agonist epibatidine (9, 11). Here, we report that ganglionic nAChR protein is expressed in SCLC cell lines derived from patients with paraneoplastic neurological autoimmunity. Rabbits immunized with a recombinant protein corresponding to the

Received for publication November 19, 2002, and accepted December 17, 2002.

Address correspondence to: Vanda A. Lennon, Mayo Clinic, Neuroimmunology Laboratory, Guggenheim Building, Room 828, 200 First Street SW, Rochester, Minnesota 55905, USA. Phone: (507) 284-7514; Fax: (507) 284-1814; E-mail: lennon.vanda@mayo.edu.

Conflict of interest: The authors have declared that no conflict of interest exists.

Nonstandard abbreviations used: myasthenia gravis (MG); nicotinic AChR (nAChR); experimental autoimmune MG (EAMG); autoimmune autonomic neuropathy (AAN); small-cell lung carcinoma (SCLC); experimental AAN (EAAN).

N-terminal extracellular domain of the nAChR $\alpha 3$ subunit produce antibodies reactive with native ganglionic nAChR and develop a severe dysautonomic syndrome — experimental AAN (EAAN). Our data indicate that AAN in human is likely a channelopathy rather than a neuropathy. It represents the first example of an acquired disorder affecting a neuronal nAChR.

Methods

Neuronal fusion proteins. cDNA encoding residues 1–205 of the human nAChR $\alpha 3$ subunit (GenBank accession number X53559) was prepared by RT-PCR amplification using total RNA isolated from IMR-32 cells. The product was subcloned into the glutathione S-transferase (GST) fusion vector pGEX-4T-1 (Amersham Biosciences, Piscataway, New Jersey, USA). A control cDNA encoding rat calcium channel $\beta 4$ subunit (residues 419–519) in a GST fusion vector pGEX-KG was provided by Kevin Campbell (University of Iowa, Iowa City, Iowa, USA). Recombinant protein synthesis was induced in transfected *E. coli* (BL21, DE-3) by isopropyl- β -D-thiogalactoside. Insoluble $\alpha 3$ -GST protein was extracted from pelleted bacteria by sequential homogenization, washing, and centrifugation in 50 mM Tris buffer alone, 1 M NaCl, 3 M NaSCN, and then 8 M urea, which was eliminated by progressive dialysis (12). Coomassie blue staining of a polyacrylamide electrophoretogram revealed that the product was approximately 70% pure. The more soluble $\beta 4$ -419–519-GST protein was purified on glutathione agarose.

Human cell lines. We established the lines designated “SCC” from small-cell carcinomas described in the Table 1 legend. SCLC lines designated “NCI” were obtained from the American Type Culture Collection (ATCC, Manassas, Virginia, USA), as were the peripheral neuroblastoma IMR-32 and the rhabdomyosarcoma TE671. Dr. William Green (University of Chicago, Chicago, Illinois, USA) provided HEK-tsA201, an embryonic kidney cell transformed with SV40 large T antigen and transfected stably with rat nAChR $\alpha 4$ and $\beta 2$ subunits (13). Culture conditions were those recommended by the ATCC.

Native nAChR subtype preparation and quantitation. We prepared membranes from cell lines grown as xenografts in immunodeficient mice (14). After homogenization,

we isolated postnuclear membrane fractions by differential centrifugation, extracted nAChR in 2% Triton X-100, and removed insoluble residue by ultracentrifugation. The following were used as control sources of nAChR subtypes: IMR-32 extract complexed with [125 I]epibatidine for $\alpha 3$ (15); IMR-32 extract complexed with [125 I] α -bungarotoxin for $\alpha 7$ (14, 15); TE671 extract complexed with [125 I] α -bungarotoxin for $\alpha 1$ (14, 15); and $\alpha 4\beta 2$ -transfected HEK-tsA201 extract complexed with [125 I]epibatidine for $\alpha 4$ (13). Total nAChR (fmol/mg of protein) was calculated from specific counts per minute assayed by vacuum filtration on polyethyleneimine-treated glass-fiber filters (16, 17). To ensure the selectivity of ligand binding to nAChR subtypes, we labeled each extract with a limiting concentration of 125 I-labeled ligand (2 nM), with and without unlabeled ligand as an inhibitor. Under these conditions, [125 I]epibatidine binds negligibly to $\alpha 1$ and $\alpha 7$ nAChRs (15). Subtype antigenicity was confirmed by quantitative immunoprecipitation using the following nAChR-specific rat monoclonal IgGs: mAb 3 (muscle and $\alpha 3$ nAChR) (15), mAb P20 (muscle nAChR) (15), mAb P27 ($\alpha 7$ nAChR) (14), and mAb 299 ($\alpha 4$ nAChR; Covance Inc., Princeton, New Jersey, USA). Rat mAb 1, specific for *Torpedo* electric organ nAChR (15), was the negative control.

Immunoprecipitation assays. Native nAChR-binding antibodies were detected by radioimmunoprecipitation (17) by mixing rabbit serum (5 μ l and serial 10-fold dilutions as needed) with an aliquot of solubilized nAChR complexed with the appropriate 125 I-labeled ligand. Molar equivalents of each specific antigen complex were added, as predetermined by glass-fiber filtration assay. Goat anti-rabbit IgG (H & L, Equitech-Bio Inc., Kerville, Texas, USA) was the precipitant. Goats immunized with rat IgG provided precipitant for rat mAbs.

General animal procedures. The Mayo Clinic Institutional Animal Care and Use Committee approved this study (A164BXZ98). Young adult female New Zealand white rabbits were restrained in a “Bunny Snuggle” (Lomir Biomedical Inc., Malone, New York, USA) for immunization, bleeding, and video fluoroscopic examination. Brief daily restraint was initiated 1 week before immunization to avoid stress effects on the immune response. We inoculated multiple dorsal midline sites intradermally with one of the neuronal GST proteins

Table 1

Frequency, subtype, and quantity of nAChR proteins detected in membranes of small-cell carcinoma and control human cell lines

Cell line	Number of cell lines	$\alpha 1$ nAChR (fmol/mg \pm SEM)	$\alpha 3$ nAChR (fmol/mg \pm SEM)	Both $\alpha 1$ and $\alpha 3$ nAChR
Small-cell: neurologic autoimmune disorder ^A	10	5 (31.2 \pm 12.86) ^B	5 (25.6 \pm 5.83) ^C	4
Small-cell: no known autoimmune neurologic disorder ^D	6	2 (14.7; 34.3) ^E	0	0
IMR-32: peripheral neuroblastoma	1	0.00	26.2	—
TE671: skeletal muscle sarcoma	1	136.0	0.00	—

^ALines SCC-2, 4, 15, 17, 18, 37, 81, 86, 99, and 136 from individual patients with paraneoplastic syndromes affecting the peripheral or central nervous system were established before cancer therapy. All were from lymph node metastases except line SCC-15 (from primary bronchial neoplasm) and line SCC-136 (from primary extrapulmonary [ovarian] neoplasm). ^BLines SCC-2, 4, 37, 81, and 99. ^CLines SCC-2, 18, 37, 81, and 99. ^DLines SCC-21 and SCC-59 were from lymph node metastases of two untreated patients, line SCC-9 was from a subcutaneous metastasis after chemotherapy, and lines NCI-H146, NCI-H82, and NCI-H69 were from pleural fluid metastases after chemotherapy. ^ELines SCC-59 and NCI-H82.

(~800 µg in PBS), or with PBS alone, emulsified in complete Freund's adjuvant. Once weekly, rabbits were weighed, given oral iron and vitamin supplements, and, from day 20, bled from the central ear artery. Athymic nude mice were inoculated subcutaneously with 10–50 million cultured human tumor-line cells and euthanized for harvesting of tumors (~2–3 g).

Gastrointestinal motility studies. Rabbits were fasted for 18 hours. Saline containing 5% dextrose (200 ml) was injected subcutaneously immediately before initial testing. To monitor gastric emptying, we began video fluoroscopy immediately after gavage of 40 ml single-contrast barium (Mallinckrodt Medical Inc., St. Louis, Missouri, USA), with the rabbit placed alternately on its abdomen and right side. Subsequent abdominal imaging was performed at 6 and 24 hours, and daily thereafter, until the barium was evacuated.

Microelectrode measurements. After lethal intravenous injection of sodium pentobarbital, inferior mesenteric ganglia with attached lumbar colonic nerves were dissected rapidly from rabbits and maintained in oxygenated Krebs's solution at 37°C. We made intracellular recordings from ganglion neurons using microelectrodes filled with 3 M KCl (input resistance, 60–100 MΩ). Membrane potential was recorded using a Duo 773 amplifier (WPI Inc., Sarasota, Florida, USA) and stored digitally in a personal computer with a Digidata 1322A (Axon Instruments Inc., Union City, California, USA). For offline analysis, we used Axoscope 8.1 software (Axon Instruments Inc.). Stimulus was applied to the lumbar colonic nerve using a bipolar electrode.

Results

Tumors express several nAChR subtypes. We quantitated nAChR proteins immunochemically in detergent-solubilized membranes prepared from 16 SCLC lines (Table 1). Of 10 lines derived from patients with a paraneoplastic neurological disorder, 5 (50%) contained measurable ganglionic nAChR protein (mean value equivalent to the value for the neuroblastoma control, IMR-32) and 5 (50%) contained measurable muscle nAChR protein (mean value 22.8% of the value for the rhabdomyosarcoma control, TE671). Four of these 10 lines (40%) expressed both ganglionic nAChR and muscle nAChR. In contrast, none of six SCLC lines derived from patients without a history of neurological autoimmunity contained ganglionic nAChR protein; two (33%) contained muscle nAChR protein.

Recombinant α3 subunit induces autoantibodies reactive with native ganglionic nAChRs. In response to a single challenge with α3-GST protein, 16 of 18 rabbits produced antibodies reactive with ganglionic nAChR. Antibody levels rose progressively from day 20 to day 50 and reached a plateau by 2 months (Figure 1a). Twelve responders were seropositive before day 21. Two rabbits lacked detectable nAChR antibody through 105 days of observation. The range of antibody values in seropositive rabbits, and the median value (Table 2), were similar to values found in serum from patients

with AAN (10). When antibody levels were at a peak, sera from 10 of the 16 responder rabbits had a low degree of cross-reactivity (0.12–4.6%) with muscle (α1) nAChR or another neuronal (α4 or α7) nAChR (Table 2). No rabbit developed clinical signs of EAMG (4), and there was no significant loss of nAChR detected in intercostal muscle harvested at autopsy (data not shown). We did not detect ganglionic nAChR antibody in six rabbits immunized with a control neuronal calcium channel–GST protein, or in six control rabbits immunized only with adjuvant. No signs of dysautonomia were observed in any control rabbit, nor in the two α3-GST-inoculated rabbits that failed to produce antibodies. In contrast, all of the 16 rabbits producing antibodies reactive with ganglionic nAChR developed signs of dysautonomia.

Gastrointestinal, bladder, and ocular manifestations of EAAN parallel serum autoantibody profile. The first sign of

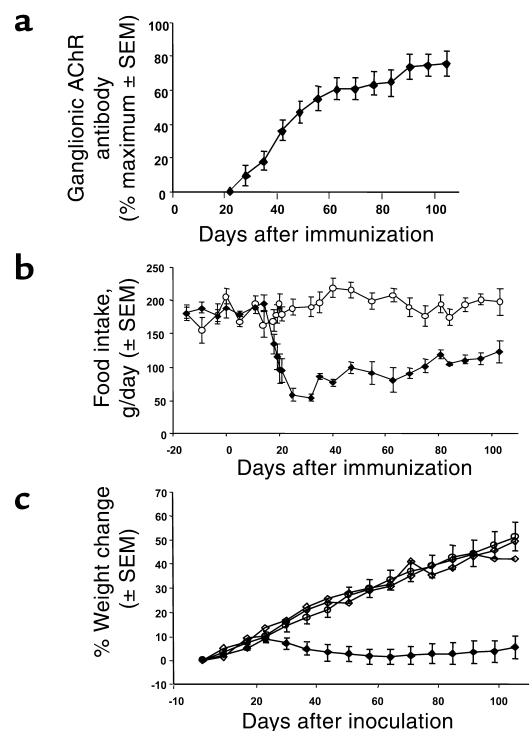


Figure 1

Clinical outcome of immunization parallels ganglionic nAChR antibody response. (a) Serial levels of antibody in serum of 16 responder rabbits expressed for each individual as a percentage of the maximal attained level (mean 9.19 ± 1.84 nmol of [125 I]epibatidine-complexed ganglionic nAChR bound per liter) and shown as means \pm SEM of all normalized values. Two rabbits of 18 challenged with α3-GST protein remained seronegative. (b) Average daily food intake (\pm SEM) in rabbits producing ganglionic nAChR antibody and controls. Filled diamonds represent five responder rabbits immunized with α3-GST fusion protein, and open circles represent six rabbits immunized with a control GST protein. (c) Serial weight changes in α3-GST responder and nonresponder rabbits. Filled diamonds represent 16 rabbits producing ganglionic nAChR antibody, open circles represent 12 control rabbits (6 immunized with control GST fusion protein and 6 with adjuvant only), and open diamonds represent 2 individual rabbits that remained seronegative after α3-GST inoculation.

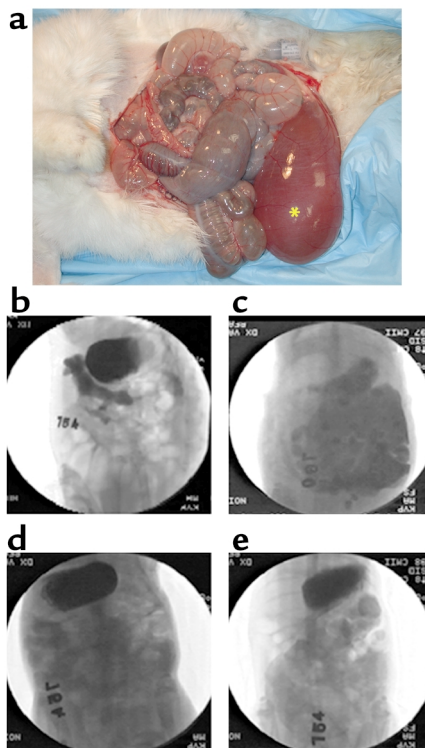


Figure 2

Dysautonomia of gut and bladder in seropositive rabbits. (a) Dilated loops of bowel (intestinal pseudo-obstruction) and enlarged bladder (megacystis, indicated by an asterisk) in a rabbit with severe EAAN. (b–e) Radiological images of barium in transit through the gut of two rabbits (orientation, head at top). Images in b, d, and e are from a rabbit with EAAN on days 74–77 after $\alpha 3$ -GST immunization. The image in c is from a control rabbit on day 74 after adjuvant only. (b) Barium (black) initially leaving enlarged stomach enters abnormally dilated proximal duodenum approximately 20 minutes after 40 ml gavage. Distended gas-filled loops of surrounding small intestine appear white. (c) At 6 hours, barium is distributed throughout the bowel of the control rabbit. (d and e) In the EAAN rabbit, most barium remains in the stomach at 6 hours (d) and at 72 hours (e). All controls evacuated barium by day 3.

EAAN was a reduction in food consumption. Daily food intake began to fall in antibody-producing rabbits between days 16 and 18 and rapidly fell below 50% of the intake of seronegative rabbits (Figure 1b). Cessation of weight gain or frank weight loss commenced after day 20. On average, weight reached a nadir at day 65 and plateaued thereafter through 105 days of observation (Figure 1c). Intestinal pseudo-obstruction and megacystis were common autopsy findings (Figure 2a). Gross bladder distention, consistent with parasympathetic denervation, was observed in 8 of 12 autopsied seropositive rabbits, but in none of 7 autopsied control rabbits, nor in an autopsied nonresponder rabbit. The rabbit with the earliest signs of EAAN had overt gastrointestinal hypomotility on day 21. Rapid progression to pseudo-obstruction necessitated euthanasia on day 29 (serum antibody level, 3.34 nmol/l). Immediate

autopsy revealed aperistalsis and massively distended loops of gas-filled intestine. The stomach was grossly enlarged by retained vegetable-fiber residue. To formally investigate gastrointestinal motility, we used video fluoroscopy to image barium in transit through the gut of 16 rabbits between days 63 and 77 after immunization (10 with $\alpha 3$ -GST fusion protein, and 6 with adjuvant alone) (Figure 2, b–e). The group inoculated with $\alpha 3$ -GST protein included one that remained seronegative. That rabbit did not differ from adjuvant-inoculated control rabbits with respect to gastrointestinal transit time or peristaltic patterns. In contrast, the five rabbits with peak ganglionic nAChR antibody levels exceeding 3.00 nmol/l had imaging evidence of gastroparesis. Three to 8 days elapsed before all barium left their stomachs, as compared with 6–24 hours for controls. Those five rabbits also had abnormal peristaltic patterns, with a conspicuous lack of normal antroduodenal coordination. At the time of testing, gastric emptying was not delayed in four rabbits with peak antibody levels lower than 2.00 nmol/l. However, two of these rabbits, and all rabbits with gastroparesis, had a delay in evacuating barium from the colon (6–28 days for seven of nine seropositive rabbits, as compared with 2–3 days for controls). Food intake increased after approximately day 65 in surviving seropositive rabbits, but weight was not regained in 7 months of observation. Diarrhea was noted in several rabbits, particularly after day 75, suggesting either bacterial overgrowth

Table 2

Serological outcome of immunization with nAChR $\alpha 3$ subunit extracellular domain (residues 1–205)

Immunogen	Number of rabbits	Native nAChR Ab responses ^A							
		Number of positive responders, median value, and range (nmol/l)							
		$\alpha 3$		$\alpha 4$		$\alpha 7$		$\alpha 1$	
nAChR $\alpha 3$ -1-205-GST	18	16	18.0	7	0.42	9	0.17	7	0.74
			0.15–143		0.14–1.83		0.08–0.68		0.05–1.37
Control GST protein ^B	6	0	0.00	0	0.00	0	0.00	0	0.00
Adjuvant alone	6	0	0.00	0	0.00	0	0.00	0	0.00

^AnAChRs solubilized from postnuclear membranes of human cell lines and complexed with a ¹²⁵I-labeled ligand. Values are moles of ¹²⁵I-labeled ligand-receptor complex bound by IgG. The source for $\alpha 3$ was IMR-32 neuroblastoma cells (ligand, epibatidine), the source for $\alpha 4$ was HEK-tsA201 cells stably transfected with rat $\alpha 4\beta 2$ nAChRs (ligand, epibatidine), the source for $\alpha 7$ was IMR-32 cells (ligand, α -bungarotoxin), and the source for $\alpha 1$ was TE671 rhabdomyosarcoma cells (ligand, α -bungarotoxin). ^BC-terminal residues 419–519 of rat neuronal calcium channel $\beta 4$ subunit.

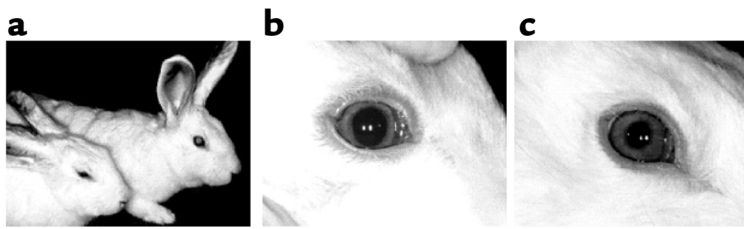


Figure 3

(a-c) Ocular signs of dysautonomia on day 28 after primary immunization. (a) Ptoxis in an $\alpha 3$ -GST responder rabbit (left), a sign of sympathetic denervation, was not observed in the adjuvant-inoculated control rabbit (right) or in seronegative rabbits. (b) In the same EAAN rabbit, lack of pupillary response to light is a sign of parasympathetic denervation. (c) Light stimulus induced prompt pupillary constriction in the control rabbit shown in a.

secondary to luminal stasis, or supervention of gut hyperperistalsis or malabsorption.

Signs of ocular dysautonomia correlated significantly with autoantibody levels ($P = 0.015$ by Fisher's exact test) and were not observed in any rabbit with a peak serum level lower than 3.00 nmol/l. Starting at day 25, 11 rabbits developed sustained ptoxis (drooping of one or both eyelids) (Figure 3a), consistent with sympathetic denervation of the levator palpebrae superioris muscle, or dilated pupils with impaired light response (compare Figures 3b and 3c), consistent with parasympathetic denervation of the pupillary constrictor muscles. Nine rabbits had both sympathetic and parasympathetic ocular signs.

Ganglion neurons fail to respond to preganglionic nerve stimulation. To directly assess ganglionic neurotransmission, we used intracellular microelectrodes to record cholinergic synaptic responses from neurons in the inferior mesenteric ganglion. These neurons are a major extrinsic regulator of colonic motility. Their postsynaptic nAChRs, which contain $\alpha 3$ subunits (18), receive cholinergic input from the spinal cord and gut (19). All of 16 neurons tested in ganglia from two control rabbits exhibited an action potential response to a single supra-

maximal electrical stimulus of lumbar colonic nerves (Figure 4a). In contrast, trans-synaptic neurotransmission failed in 15 of 22 neurons tested in ganglia from four rabbits with EAAN (Figure 4b). Neurons in EAAN ganglia that did respond to synaptic stimulation failed more frequently upon repetitive stimulation at increasing rates, and at lower rates of stimulation (Figure 4d), than did neurons in control ganglia (Figure 4c). This indicated a reduced safety margin for transmission at the ganglionic synapse in rabbits with EAAN. All of the nonresponding neurons were viable as judged by a normal resting membrane potential (47.1 ± 1.4 mV in EAAN, $n = 22$;

47.6 ± 1.8 mV in control, $n = 16$) and a normal action potential response to direct depolarization (Figure 4, a and b). This observation implies loss of number or function of postsynaptic ganglionic nAChRs rather than cytotoxic damage to neurons.

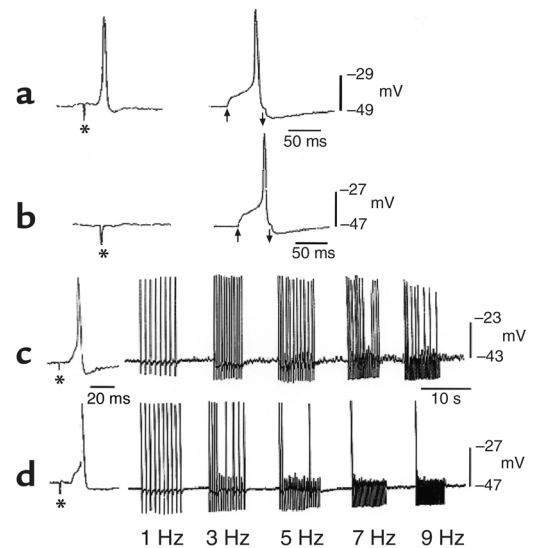
Discussion

The data we present justify classification of autoimmune autonomic neuropathy as a channelopathy involving the postsynaptic nAChR of neurons in autonomic ganglia. EAAN is the first animal model of autoimmunity affecting a neuronal nAChR. It provides a valuable tool for investigating neuronal synaptic function and basic autonomic physiology, particularly the neural circuitry regulating gut motility. Insights gained will be directly applicable to advancing the classification and therapy of other acquired autonomic neuropathies. EAAN reproduces the cardinal features of AAN in humans (10): subacute onset, dysautonomic severity paralleling the serum level of ganglionic nAChR antibody, prominent gastrointestinal dysmotility, urinary retention, and abnormal pupillary response to light.

The significant correlation of antibody level with severity of dysautonomia in both AAN and EAAN

Figure 4

(a-d) Responses of inferior mesenteric ganglion neurons to preganglionic and direct electrical stimulation. (a) Action potential response to single supramaximal stimulus of lumbar colonic nerve in a neuron from a control rabbit (120 V for 1 ms, indicated by an asterisk) and subsequently on direct neuronal depolarization (0.15 nA for 50 ms, indicated by arrows). (b) In a ganglion neuron from a rabbit with severe EAAN, a single supramaximal stimulus to the lumbar colonic nerve (150 V for 1 ms, indicated by an asterisk) does not elicit any response, but direct neuronal depolarization (as in a) elicits an action potential. (c and d) Supramaximal stimulation of lumbar colonic nerves (100 V for 0.5 ms and 120 V for 0.5 ms, respectively) applied once (asterisks) or repetitively at increasing rates elicited repetitive action potential responses from the ganglion neuron of a control rabbit (c) and a rabbit with relatively mild EAAN (d). Synaptic transmission failed more frequently and at lower rates of stimulation in neurons from rabbits with EAAN.



suggests that antibody has a pathogenic role in impairing autonomic synaptic transmission, but this remains to be determined experimentally. If antibody is the effector of synaptic transmission failure, the mechanism likely involves cross-linking, internalization, and accelerated degradation of postsynaptic $\alpha 3$ nAChRs, as has been shown to occur with muscle nAChRs in EAMG and MG (6) and with motor nerve-terminal calcium channels in the Lambert-Eaton myasthenic syndrome (20). At the time points in EAAN evolution that we studied in this report, neurons in the inferior mesenteric ganglion were viable, despite failing to respond to preganglionic nerve stimulation. Viability would not be anticipated in neurons sustaining lytic attack by complement or by cytotoxic effector immune cells. Blocking of agonist binding by ganglionic nAChR antibody is another potential effector mechanism. However, ganglionic nAChR-blocking antibody is uncommon in serum from patients with AAN (10).

The antibody response accompanying EAAN in this study was largely specific for synaptic ganglionic nAChRs, a majority of which are $\alpha 3\beta 4$ pentamers (11). The nAChR autoantibodies in patients with AAN also are largely specific for $\alpha 3$ -containing nAChRs, with a low level of coexisting muscle nAChR antibody in a minority of patients (15). The observed autonomic defects in neonatal transgenic mice with a null mutation for the nAChR $\alpha 3$ subunit (21) or double null mutations for the $\beta 4$ and $\beta 2$ subunits, which are interchangeable partners for $\alpha 3$ in ganglionic nAChRs (22), support our conclusion that the dysautonomia of EAAN reflects a selective attack on nAChRs that contain $\alpha 3$ subunits. This conclusion is also consistent with the reported absence of nAChR $\alpha 3$ subunit mRNA and immunoreactive protein in enteric neuronal tissues of infants with the megacystis-microcolon-intestinal hypoperistalsis syndrome (23). Ptosis is a common sign of EAAN in the rabbit and may be seen in patients with AAN (24) but is not evident in rabbits or rodents with EAMG (4, 5). This most likely reflects a larger contribution of sympathetic than somatic innervation to the eyelid levator in rabbits and rodents. Accordingly, ptosis is evident in $\alpha 3$ null mutant mice, $\alpha 2\beta 4$ double-null mutants, and in rats with an immunosympathectomy induced by administration of nerve growth factor antibodies at birth (25) or acetylcholinesterase antibodies in adulthood (26). Those antibodies destroy ganglionic (25) and preganglionic neurons (27), respectively, in the superior cervical ganglion.

There is a recognized link between ectopic expression of neuronal and muscle autoantigens in certain cancers, particularly SCLC (14, 28–30), and the finding in a patient's serum of corresponding marker antibodies, some of which have pathogenic potential (14, 28, 29, 31). This relationship is best illustrated by the calcium channel antibodies that cause presynaptic failure of neuromuscular transmission in the Lambert-Eaton syndrome (20, 28, 29). Several neuronal nAChR subtypes, as well as muscle nAChR, have pre-

viously been found in SCLC cell lines. Functional studies in SCLC cell lines suggest that these ligand-gated cation channels may act in synergy with voltage-gated calcium channels (14) to influence transcription of growth-regulatory genes. They also regulate cell proliferation and secretion of autocrine growth factors (32–35). To our knowledge, our present report is the first to identify a neuronal nAChR of postsynaptic ganglionic type in SCLC lines. It is interesting that our analyses to date infer restriction of this antigen to tumor cells derived from patients with clinical evidence of paraneoplastic autoimmunity. We propose that immune responses driven by the different nAChR subtypes expressed in this cancer account for several of the related paraneoplastic neurological disorders affecting cholinergic systems, including AAN, limbic encephalopathy, and movement disorders. Continued investigation of the immunogenicity and antigenicity of neuronal nAChR subtypes can be expected to yield information pertinent to both neurological autoimmunity and tumor immunology.

Note added in proof. A chronic form of AAN, analogous to EAAN of slow onset in the rabbit has recently been recognized clinically (36).

Acknowledgments

We thank G.E. Griesmann, T.J. Kryzer, E. Posthumus, E. Swanson, and J. Thoreson for expert technical assistance; W.N. Green (University of Chicago) for providing the $\alpha 4/\beta 2$ -transfected HEK-ts A201 cell line; and K.P. Campbell (Howard Hughes Medical Institute, University of Iowa) for providing DNA plasmid encoding rat calcium channel $\beta 4$ subunit. This work was supported by the Lee Pearce Foundation, the Mayo Clinic Cancer Center, and NIH grants CA37343 (to V.A. Lennon), NS02247 (to S. Vernino), and DK17636 (to J.H. Szurszewski).

1. Musunuru, K., and Darnell, R.B. 2001. Review. Paraneoplastic neurologic disease antigens: RNA-binding proteins and signaling proteins in neuronal degeneration. *Annu. Rev. Neurosci.* **24**:239–262.
2. Steinman, L., Martin, R., Bernard, C., Conlon, P., and Oksenberg, J.R. 2002. Multiple sclerosis: deeper understanding of its pathogenesis reveals new targets for therapy. *Annu. Rev. Neurosci.* **25**:491–505.
3. Willison, H., Stoll, G., Toyka, K.V., Berger, T., and Hartung, H.P. 2002. Autoimmunity and inflammation in the peripheral nervous system. Research update. *Trends Neurosci.* **25**:127–129.
4. Patrick, J., and Lindstrom, J. 1973. Autoimmune response to acetylcholine receptor. *Science.* **180**:871–872.
5. Lennon, V.A., Lindstrom, J.M., and Seybold, M.E. 1975. Experimental autoimmune myasthenia: a model of myasthenia gravis in rats and guinea pigs. *J. Exp. Med.* **141**:1365–1375.
6. Drachman, D.B. 1994. Myasthenia gravis. *N. Engl. J. Med.* **330**:1797–1810.
7. Picciotto, M.R., et al. 2001. Neuronal nicotinic acetylcholine receptor subunit knockout mice: physiological and behavioral phenotypes and possible clinical implications. *Pharmacol. Ther.* **92**:89–108.
8. Li, M., and Lester, H.A. 2001. Ion channel diseases of the central nervous system. *CNS Drug Rev.* **7**:214–240.
9. Lukas, R.J., et al. 1999. International Union of Pharmacology. XX. Current status of the nomenclature for nicotinic acetylcholine receptors and their subunits. *Pharmacol. Rev.* **51**:397–401.
10. Vernino, S., et al. 2000. Autoantibodies to ganglionic acetylcholine receptors in autoimmune autonomic neuropathies. *N. Engl. J. Med.* **343**:847–855.
11. Nelson, M.E., et al. 2001. Functional properties of human nicotinic AChRs expressed by IMR-32 neuroblastoma cells resemble those of

- alpha3beta4 AChRs expressed in permanently transfected HEK cells. *J. Gen. Physiol.* **118**:563–582.
12. Schoepfer, R., Halvorsen, S.W., Conroy, W.G., Whiting, P., and Lindstrom, J. 1989. Antisera against an acetylcholine receptor $\alpha 3$ fusion protein bind to ganglionic but not to brain nicotinic acetylcholine receptors. *FEBS Lett.* **257**:393–399.
 13. Buisson, B., Vallejo, Y.F., Green, W.N., and Bertrand, D. 2000. The unusual nature of epibatidine responses at the $\alpha 4\beta 2$ nicotinic acetylcholine receptor. *Neuropharmacology.* **39**:2561–2569.
 14. Sciamanna, M.A., Griesmann, G.E., Williams, C.L., and Lennon, V.A. 1997. Nicotinic acetylcholine receptors of muscle and neuronal ($\alpha 7$) types coexpressed in a small cell lung carcinoma. *J. Neurochem.* **69**:2302–2311.
 15. Vernino, S., Adamski, J., Kryzer, T.J., Fealey, R.D., and Lennon, V.A. 1998. Neuronal nicotinic ACh receptor antibody in subacute autonomic neuropathy and cancer-related syndromes. *Neurology.* **50**:1806–1813.
 16. Bruns, R., Lawson-Wendling, K., and Pugsley, T. 1983. A rapid filtration assay for soluble receptors using polyethyleneimine-treated filters. *Anal. Biochem.* **132**:74–81.
 17. Vernino, S., Kryzer, T.J., and Lennon, V.A. 2002. Autoimmune autonomic neuropathy and neuromuscular hyperexcitability disorders. In *Manual of clinical and laboratory immunology*, 6th edition. N.R. Rose, R.G. Hamilton, and B. Detrick, editors. ASM Press. Washington, DC, USA. 1013–1017.
 18. Ermilov, L.G., et al. 1995. Simultaneous 3-D detection of nicotinic acetylcholine receptor clusters and VIP-ergic synaptic boutons in guinea pig peripheral autonomic ganglia. *Gastroenterology.* **108**:A963. (Abstr.)
 19. Szurszewski, J.H., and Miller, S.M. 1994. Physiology of prevertebral ganglia. In *Physiology of the gastrointestinal tract*, 3rd edition. L.R. Johnson, editor. Raven Press. New York, New York, USA. 795–877.
 20. Fukunaga, H., Engel, A.G., Lang, B., Newsom-Davis, J., and Vincent, A. 1983. Passive transfer of Lambert-Eaton myasthenic syndrome with IgG from man to mouse depletes the presynaptic membrane active zones. *Proc. Natl. Acad. Sci. U. S. A.* **80**:7636–7640.
 21. Xu, W., et al. 1999. Megacystis, mydriasis, and ion channel defect in mice lacking the alpha3 neuronal nicotinic acetylcholine receptor. *Proc. Natl. Acad. Sci. U. S. A.* **96**:5746–5751.
 22. Xu, W., et al. 1999. Multiorgan autonomic dysfunction in mice lacking the $\beta 2$ and the $\beta 4$ subunits of neuronal nicotinic acetylcholine receptors. *J. Neurosci.* **19**:9298–9305.
 23. Richardson, C.E., et al. 2001. Megacystis-microcolon-intestinal hypoperistalsis syndrome and the absence of the $\alpha 3$ nicotinic acetylcholine receptor subunit. *Gastroenterology.* **121**:350–357.
 24. Goldstein, D.S., et al. 2002. Pandysautonomia associated with impaired ganglionic neurotransmission and circulating antibody to the neuronal nicotinic receptor. *Clin. Auton. Res.* **12**:281–285.
 25. Zaimis, E. 1965. The immunosympathectomized animal: a valuable tool in physiological and pharmacological research. *J. Physiol.* **177**:35P–36P.
 26. Brimijoin, S., and Lennon, V.A. 1990. Autoimmune preganglionic sympathectomy induced by acetylcholinesterase antibodies. *Proc. Natl. Acad. Sci. U. S. A.* **87**:9630–9634.
 27. Brimijoin, S., Moser, V., Hammond, P., Oka, N., and Lennon, V.A. 1993. Death of intermedio-lateral spinal cord neurons follows selective, complement-mediated destruction of peripheral preganglionic sympathetic terminals by acetylcholinesterase antibodies. *Neuroscience.* **54**:201–223.
 28. Lennon, V.A., et al. 1995. Calcium-channel antibodies in Lambert-Eaton myasthenic syndrome and other paraneoplastic syndromes. *N. Engl. J. Med.* **332**:1467–1474.
 29. Roberts, A., Perera, S., Lang, B., Vincent, A., and Newsom-Davis, J. 1985. Paraneoplastic myasthenic syndrome IgG inhibits ^{45}Ca flux in human small cell carcinoma line. *Nature.* **317**:737–739.
 30. Yu, Z., et al. 2001. CRMP-5 neuronal autoantibody: marker of lung cancer and thymoma-related autoimmunity. *Ann. Neurol.* **49**:146–154.
 31. Griesmann, G.E., Harper, C.M., and Lennon, V.A. 1998. Paraneoplastic myasthenia gravis and lung carcinoma: distinction from Lambert-Eaton syndrome and hypothesis of aberrant muscle acetylcholine receptor (AChR) expression. *Muscle Nerve.* **7**(Suppl.):S122.
 32. Maneckjee, R., and Minna, J.D. 1990. Opioid and nicotine receptors affect growth regulation of human lung cancer cell lines. *Proc. Natl. Acad. Sci. U. S. A.* **87**:3294–3298.
 33. Chini, B., Clementi, F., Hukovic, N., and Sher, E. 1992. Neuronal-type α -bungarotoxin receptors and the $\alpha 5$ -nicotinic receptor subunit gene are expressed in neuronal and nonneuronal human cell lines. *Proc. Natl. Acad. Sci. U. S. A.* **89**:1572–1576.
 34. Codignola, A., et al. 1994. Serotonin release and cell proliferation are under the control of α -bungarotoxin-sensitive nicotinic receptors in small-cell lung carcinoma cell lines. *FEBS Lett.* **342**:286–290.
 35. Quik, M., Chan, J., and Patrick, J. 1994. Alpha-bungarotoxin blocks the nicotinic receptor mediated increase in cell number in a neuroendocrine cell line. *Brain Res.* **655**:161–167.
 36. Klein, C.M., et al. 2003. The spectrum of autoimmune autonomic neuropathies. *Ann. Neurol.* In press.